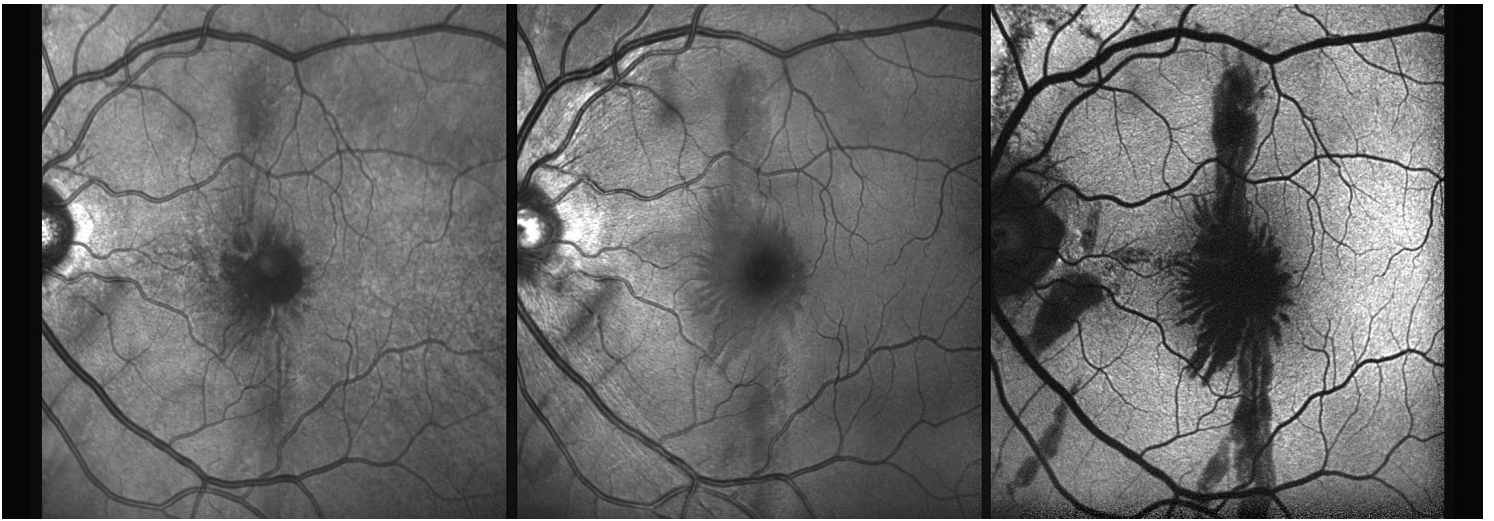
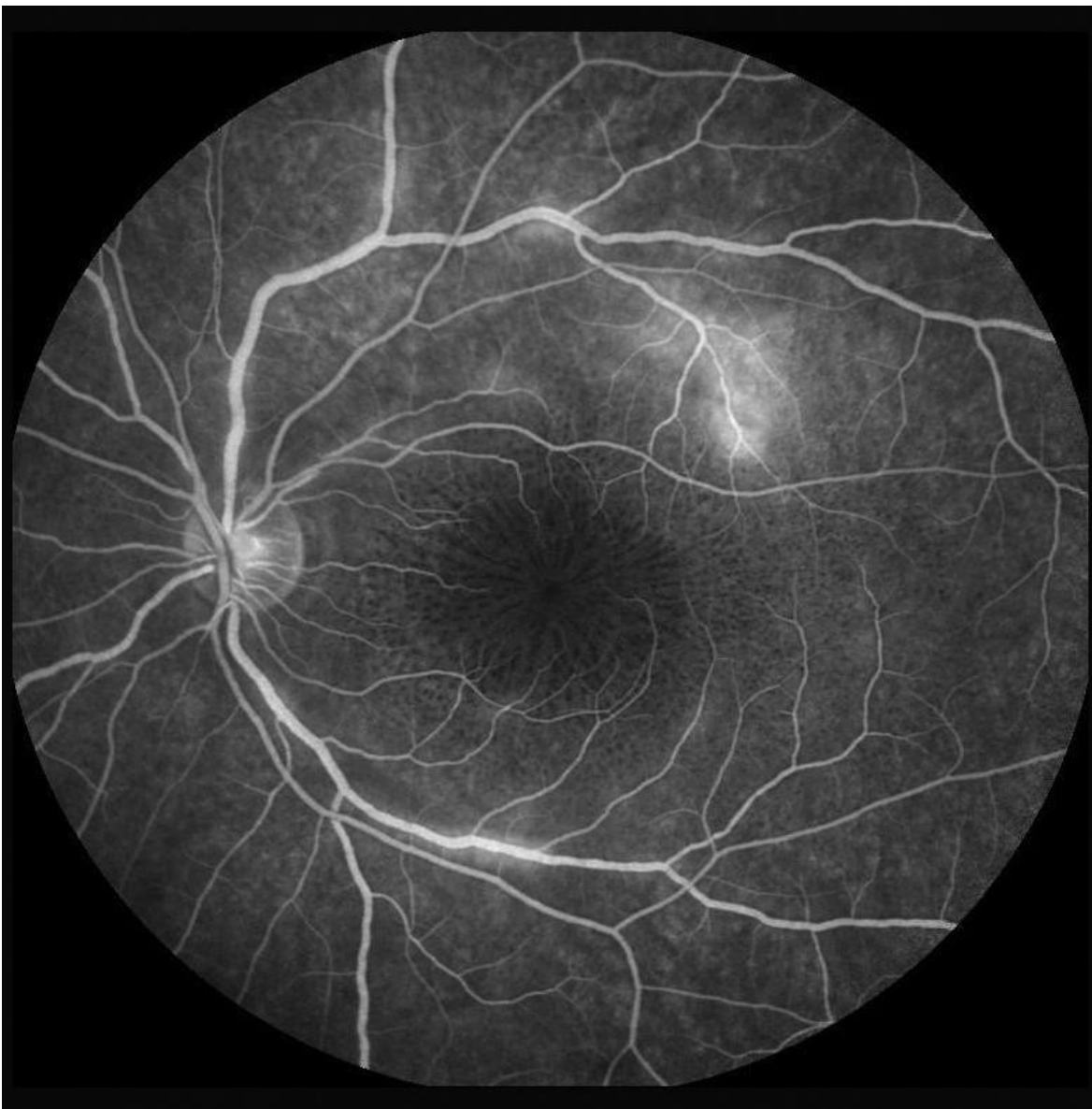

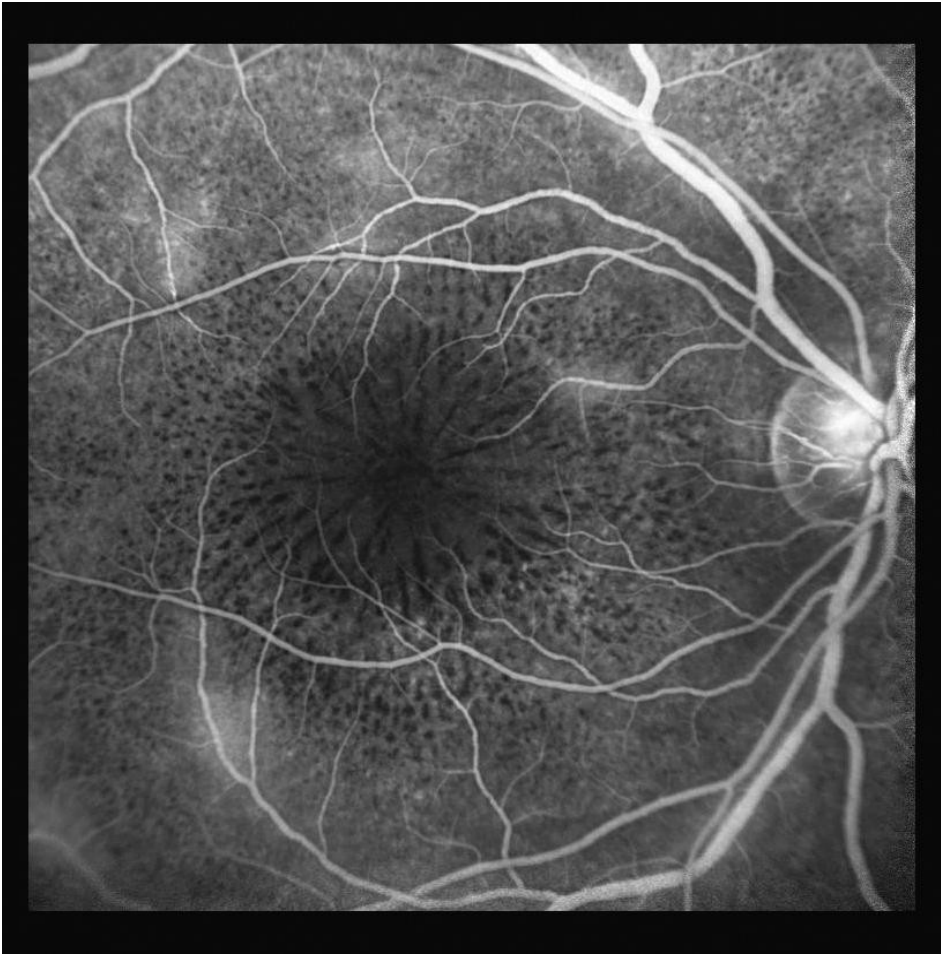
Honorable Mention - CROSS CATEGORIES / Submacular Hemorrhage after Retinal Contusion (IR, RF, FAF)



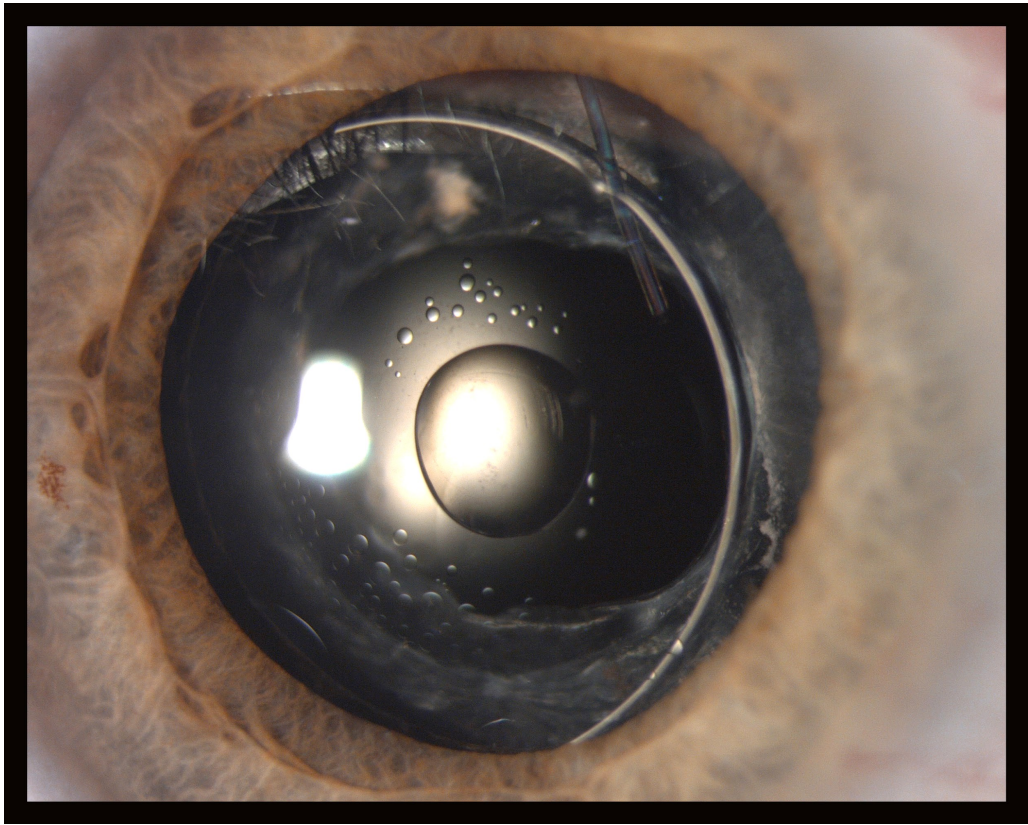
Honorable Mention - FLUORESCIN ANGIOGRAM CATEGORIE/ Neuroretinitis



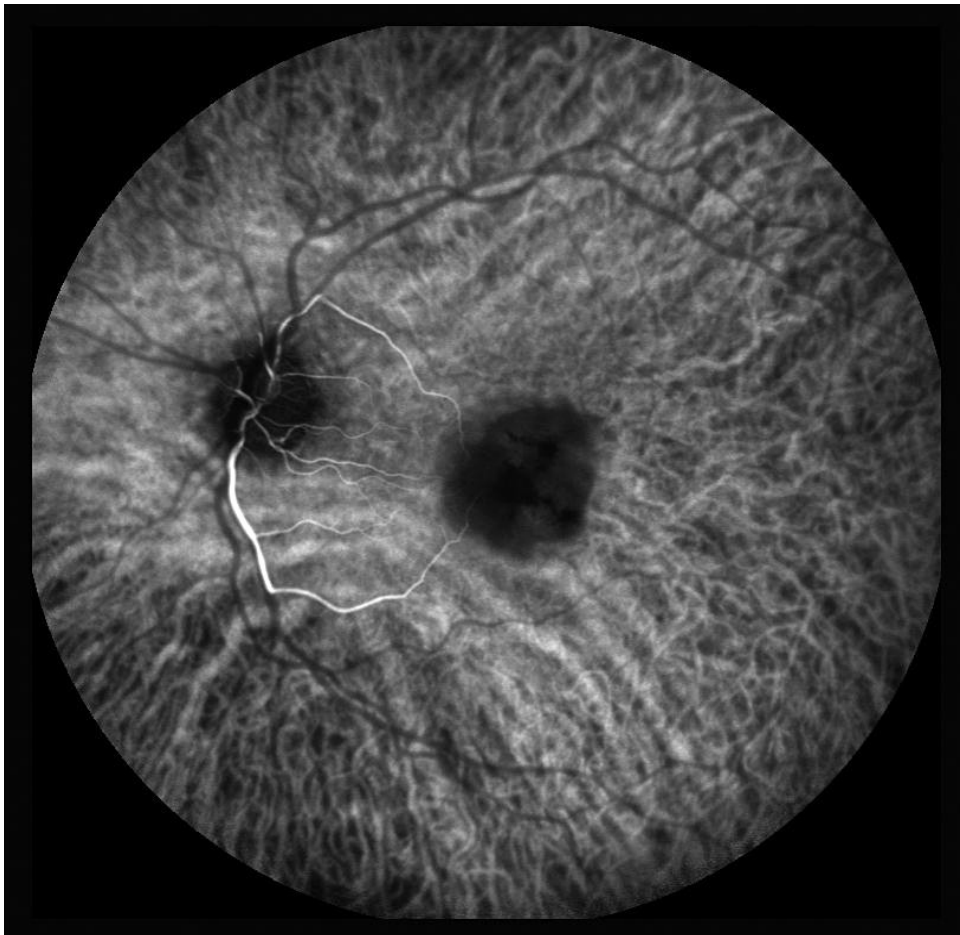Third Place - FLUORESCIN ANGIOGRAM CATEGORIE/ Neuroretinitis



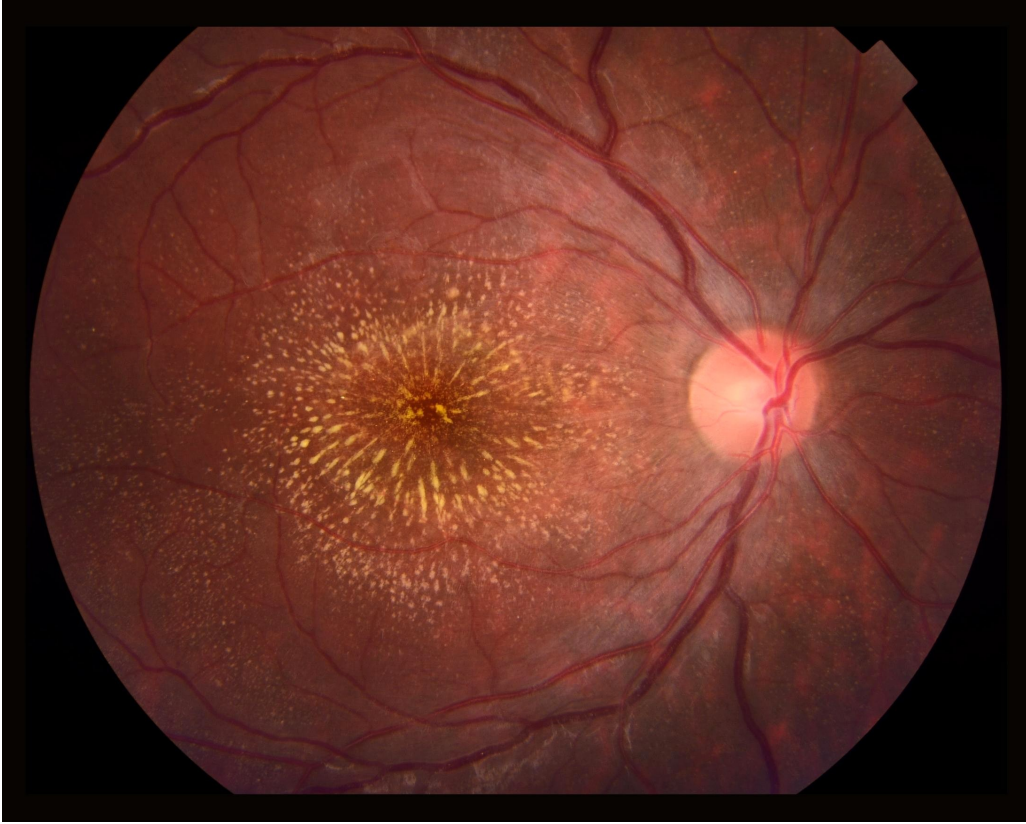Third place - SLIT LAMP PHOTOGRAPHY / Silicon Oil in Anterior Chamber



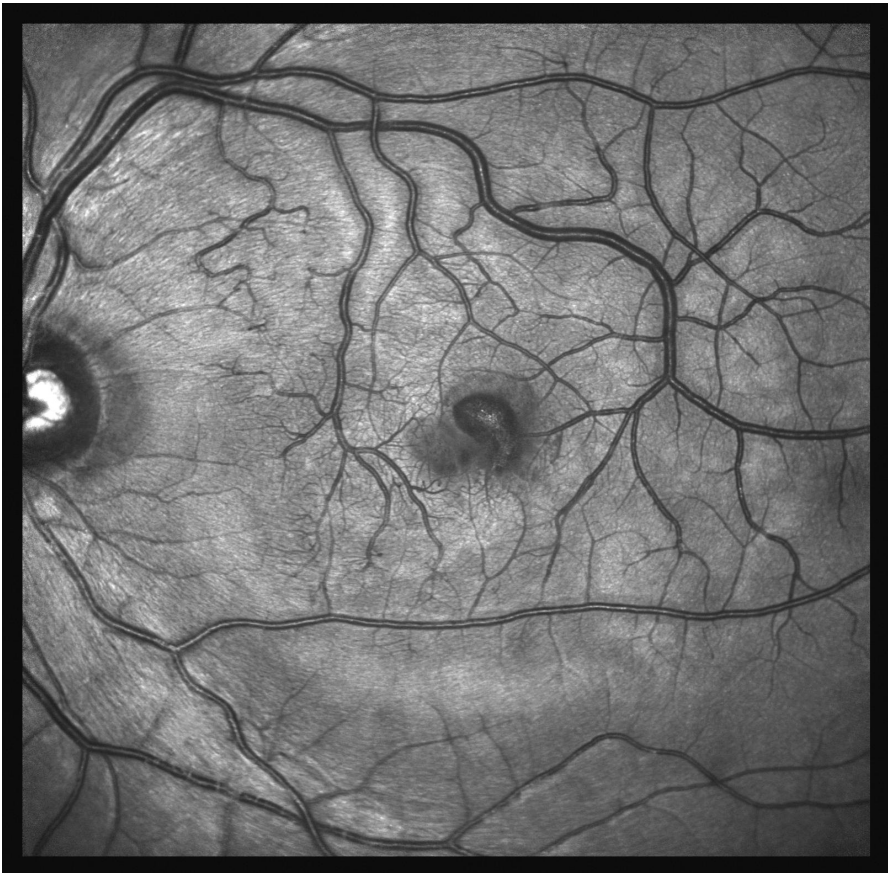Second Place - ICG ANGIOGRAM CATEGORIE/ Central Retinal Artery Occlusion



Second Place - FUNDUS PHOTOGRAPHY / Neuroretinitis



Second Place - MONOCHROMATIC PHOTOGRAPHY / Valsalva Retinopathy



First Place - COMPOSITE CATEGORIE / Probably Inflammatory Pigmented Paravenous Retinochoroidal Atrophy

